



Medical Technology

DANB-RHS Exam

DANB's Radiation Health and Safety (RHS)

DEMO Version

Full Version Features:

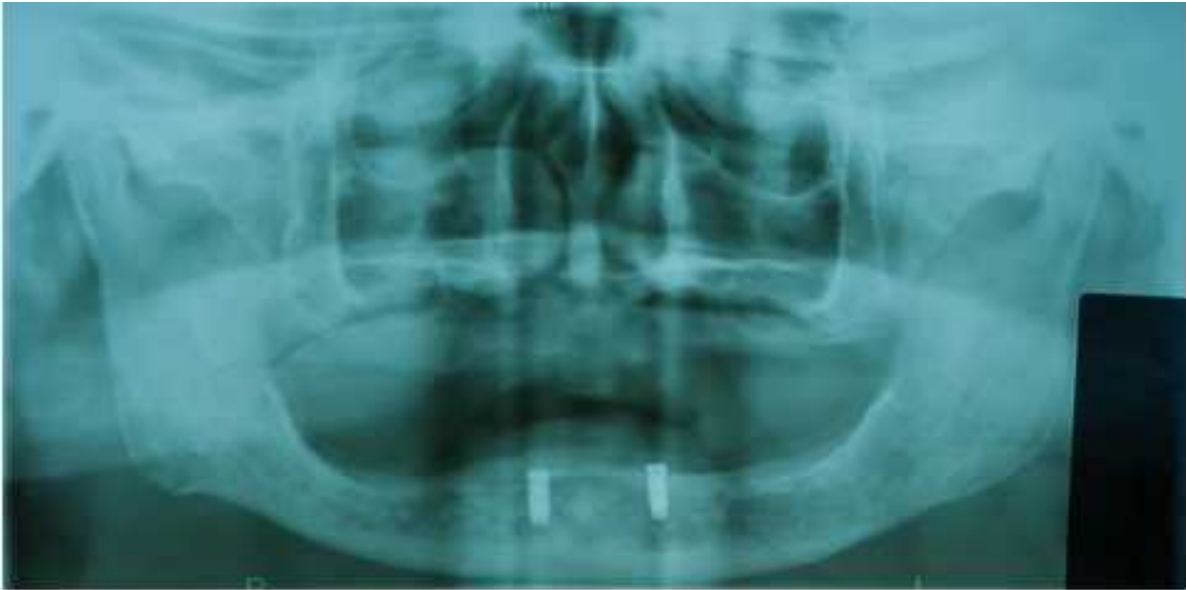- 90 Days Free Updates
- 30 Days Money Back Guarantee
- Instant Download Once Purchased
- 24 Hours Live Chat Support

Full version is available at link below with affordable price.

<https://www.practicetestsoftware.com/medical-technology/danb-rhs>

Question 1. (Single Select)

Which of these best describes this x-ray?



- A: Bitewing, showing caries.
- B: Bitewing, showing teeth implants.
- C: Full mouth, showing teeth implants.
- D: Full mouth, showing caries.

Correct Answer: C

Explanation:

The correct answer to the question "Which of these best describes this x-ray?" is "Full mouth, showing teeth implants." This is because the description clearly states that the x-ray is a full mouth type and shows teeth implants specifically on the bottom jaw.

To understand why this is the correct answer, it's important to know about different types of dental x-rays and what they show. A "full mouth" x-ray, often referred to as a panoramic or panorex x-ray, captures the entire mouth in a single image, including all the teeth of the upper and lower jaw. This type of x-ray is particularly useful for getting a comprehensive view of the oral cavity and is commonly used to plan treatments that involve multiple teeth, like implants.

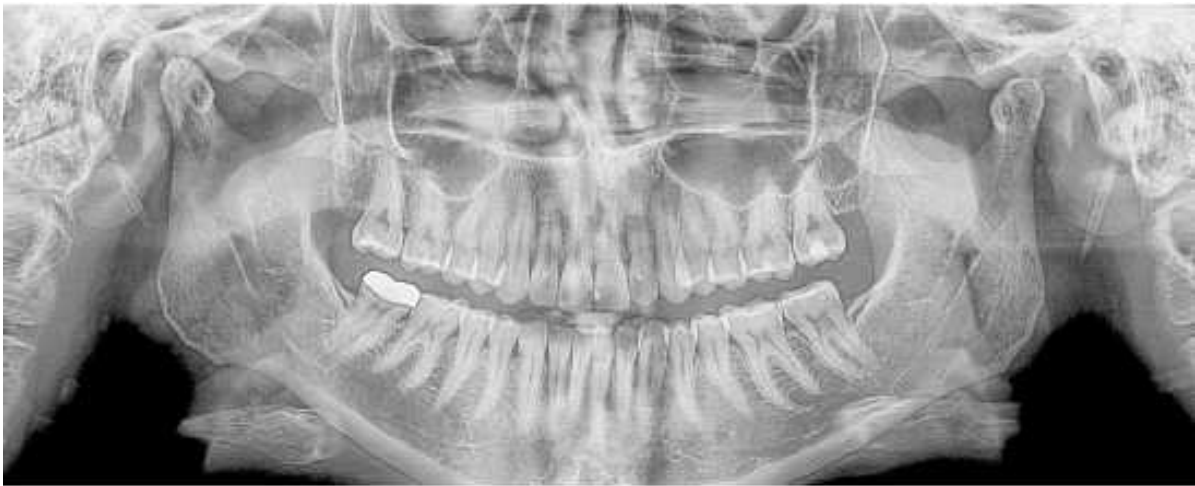In contrast, a "bitewing" x-ray focuses on the crowns of the upper and lower teeth and is typically used to detect cavities between teeth where the crowns meet. Since the question specifically mentions that the x-ray shows implants rather than cavities and includes both the upper and lower teeth, the bitewing option

can be ruled out.

The remaining answers are variations of the full mouth x-ray description. However, the answer that specifically and accurately describes the x-ray as showing teeth implants in the bottom jaw while being a full mouth x-ray is the most precise and correct choice. This eliminates any similar options that do not mention the implants or incorrectly describe another focus, such as caries (tooth decay), which is not indicated in the description provided.

Question 2. (Single Select)

How many crowns does the patient have?



A: 4

B: 1

C: 3

D: 2

Correct Answer: B

Explanation:

To answer the question regarding the number of crowns the patient has, it is essential to refer to the panoramic x-ray provided. A panoramic x-ray is a type of full-mouth X-ray that captures the entire dental arch of a patient in a single image. It is commonly used to provide a comprehensive view of the teeth, jawbones, and surrounding structures, which helps in diagnosing dental conditions and planning treatments.

In this specific case, the x-ray reveals that the patient has one crown. Dental crowns are cap-like structures

placed over a tooth, primarily used to restore its shape, size, strength, or to improve its appearance when a tooth is damaged or decayed. Crowns can be made from various materials such as porcelain, ceramic, metal, or resin.

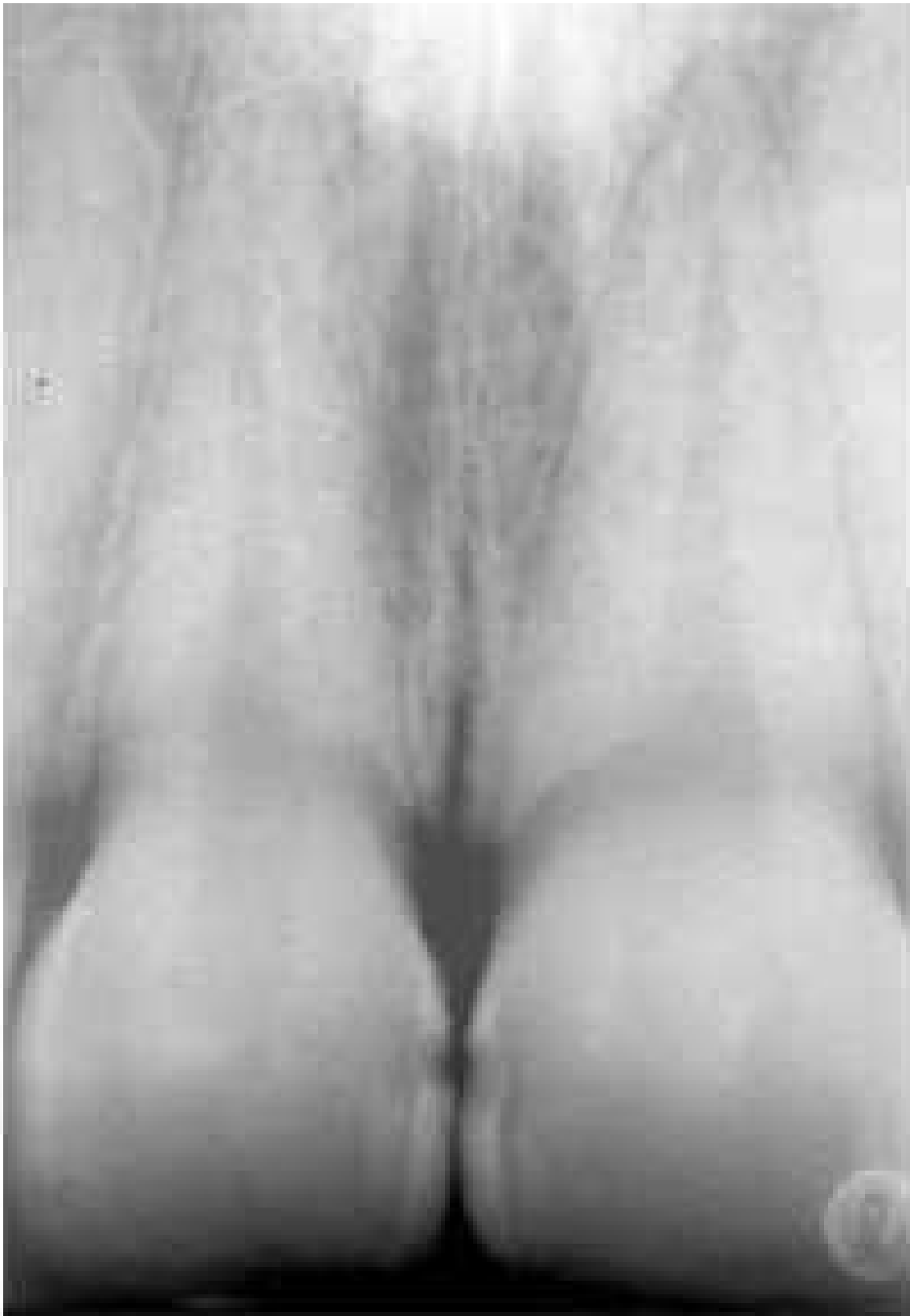
Besides the crown, the x-ray also shows several cavities. Cavities, or dental caries, are decayed areas of teeth that develop into tiny openings or holes. They are caused by a combination of factors, including bacteria in the mouth, frequent snacking, sipping sugary drinks, and not cleaning teeth well.

The presence of one crown and several cavities indicates specific dental health issues and treatment history. The crown suggests a previous significant tooth repair, while the cavities point to areas where oral hygiene may need improvement or where further dental treatments might be necessary to prevent further decay and maintain oral health.

From this information, the correct answer to the question, as shown in the x-ray, is that the patient has one crown. This answer is deduced by clearly identifying the crown among other dental structures and issues such as cavities, as visible in the panoramic x-ray.

Question 3. (Single Select)

What is the location of the cavities in this patient's teeth.



- A: In the back molars.
- B: Between the front teeth.
- C: In all of the wisdom teeth.
- D: The patient has no cavities.

Explanation:

The question pertains to identifying the location of cavities in a patient's teeth based on an x-ray image provided. Cavities, also known as dental caries, are areas of decay caused by bacteria that demineralize and destroy the hard tissues of the teeth. These are common in areas where dental hygiene is compromised and can occur between teeth, on the biting surfaces, and around old fillings or damaged areas of teeth.

In the specific case discussed in the question, the correct answer is that the cavities are located between the front teeth. This region, often referred to as the interdental or interproximal space, is particularly susceptible to the development of cavities for several reasons. Firstly, it is a region that easily traps food particles and is less efficiently cleaned by regular brushing, especially if not complemented by flossing. Secondly, these areas are less exposed to the natural self-cleaning actions of the tongue and saliva, making them more prone to plaque accumulation.

The x-ray image serves as a crucial diagnostic tool in confirming the presence of cavities. On dental x-rays, cavities typically appear as dark spots or shadows indicating areas where the tooth structure has been compromised. The radiographic evidence of cavities between the front teeth likely shows such darkened areas on the sides of these teeth where they touch each other. This is consistent with the description provided in the correct answer.

It's important to note that the other options provided in the question—cavities in the back molars, in all of the wisdom teeth, or the absence of any cavities—were incorrect based on the x-ray findings. Molars and wisdom teeth are common locations for cavities due to their complex surface anatomy that makes them harder to clean. However, in this specific patient's case, the x-ray did not show evidence of cavities in these areas.

Identifying the correct location of cavities helps in planning appropriate dental treatments, which may include fillings, crowns, or other restorative procedures to prevent further decay and restore the function and aesthetics of the teeth. Early detection and treatment are crucial in preventing more severe dental problems and maintaining overall dental health.

Question 4. (Single Select)

What line will help keep the patient's chin from tipping too far up or down?

- A: Alar-tragus line.
- B: Bite block.
- C: Edentulous guide.

D: Endoray II film holder.

Correct Answer: A

Explanation:

The correct line to help keep the patient's chin from tipping too far up or down during dental imaging is the *Alar-tragus line*.

The Alar-tragus line, often used in panoramic radiography, plays a crucial role in ensuring the patient's head is positioned accurately. This imaginary line runs from the *alar* (outer part of the nostril) to the *tragus* (the small cartilaginous bump in front of the ear canal). Proper alignment along this line is essential for capturing a clear and distortion-free panoramic image.

When positioning a patient for a panoramic X-ray, the technician adjusts the patient's head so that the Alar-tragus line is parallel to the floor. This alignment helps to prevent the chin from tipping too far upward or downward. If the chin is tilted too high, it can lead to a foreshortening of the jaw in the image, making the lower structures appear smaller than they are. Conversely, if the chin is tilted too low, it can cause elongation, making the lower jaw structures appear unnaturally stretched.

In most panoramic X-ray machines, there are visual aids or markers to help the operator in aligning the Alar-tragus line correctly. Ensuring this line is properly aligned is fundamental in achieving a diagnostic-quality image, which is crucial for accurate assessment and treatment planning in dentistry. Therefore, the Alar-tragus line is not just a guideline but a critical component in dental imaging that aids in the correct positioning of the patient, thus ensuring that the resulting images are as informative and useful as possible.

Question 5. (Single Select)

What will help a patient with a severe gag reflex?

- A: Distract the patient.
- B: Start with the largest film size.
- C: Use a bite rod.
- D: Use a round film holder.

Correct Answer: A

Explanation:

When a patient has a severe gag reflex, managing this reflex effectively is crucial for the successful completion of dental procedures. A gag reflex is a natural defense mechanism that helps prevent choking or swallowing foreign objects. However, it can pose challenges during dental treatments, especially those that involve placing objects like X-ray films or dental instruments in the mouth.

One effective strategy to help a patient with a severe gag reflex is to distract the patient. Distraction techniques can redirect the patient's attention away from the procedure and reduce the likelihood of triggering the gag reflex. Various methods can be employed for distraction: - Engaging the patient in conversation on unrelated and pleasant topics. - Allowing the patient to listen to music through headphones. - Encouraging the patient to focus on breathing exercises or visualization techniques.

In addition to distraction, there are practical approaches in handling dental tools and materials that can help minimize gag reflex activation: - **Starting with smaller film sizes:** For dental X-rays, it's beneficial to begin with smaller film sizes if the patient experiences a strong gag reflex. This minimizes the amount of foreign material in the mouth and allows the patient to gradually adapt to the sensation. - **Progressing to larger film sizes gradually:** After the patient becomes comfortable with smaller films, gradually introduce larger sizes. This step-wise approach can help desensitize the gag reflex over time.

Other tools and techniques that might be considered include: - **Using a bite rod:** This can help stabilize the film and reduce the need for the patient to adjust their mouth too frequently, which might trigger gagging. - **Employing a round film holder:** This type of holder might fit more comfortably in the mouth, reducing discomfort and potential gag reflex activation.

Overall, managing a patient with a severe gag reflex requires a thoughtful approach, combining psychological techniques such as distraction with practical adjustments to the dental tools and procedures. By doing so, dental care professionals can ensure a more comfortable and successful treatment experience for their patients.

Full version is available at link below with affordable price.

<https://www.practicetestsoftware.com/medical-technology/danb-rhs>

40% Discount Coupon Code: GET40