

Medical Technology

DANB-RHS

DANB's Radiation Health and Safety (RHS)

- Up to Date products, reliable and verified.
- Questions and Answers in PDF Format.

For More Information – Visit link below:

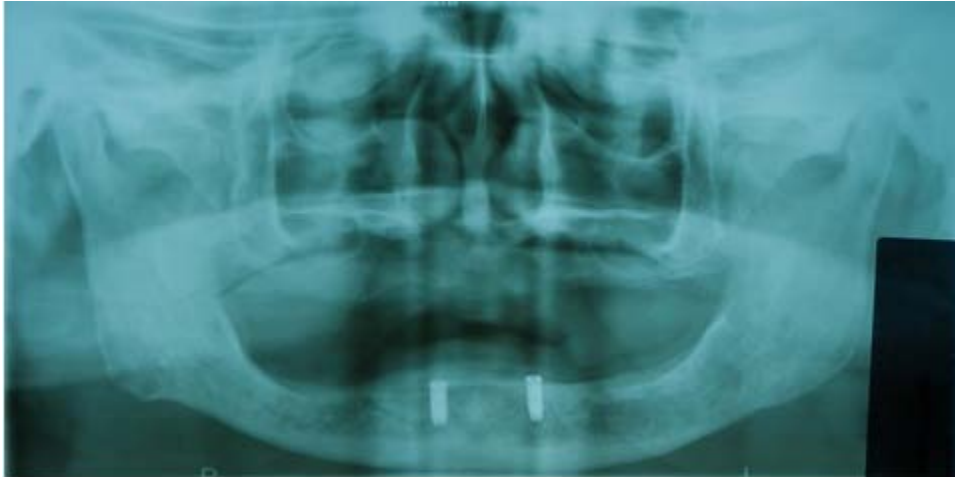[Web: www.examkill.com/](http://www.examkill.com/)

Version product

Latest Version: 6.0

Question: 1

Which of these best describes this x-ray?



- A. Bitewing, showing caries.
- B. Bitewing, showing teeth implants.
- C. Full mouth, showing teeth implants.
- D. Full mouth, showing caries.

Answer: C

Explanation:

The correct answer to the question "Which of these best describes this x-ray?" is "Full mouth, showing teeth implants." This is because the description clearly states that the x-ray is a full mouth type and shows teeth implants specifically on the bottom jaw.

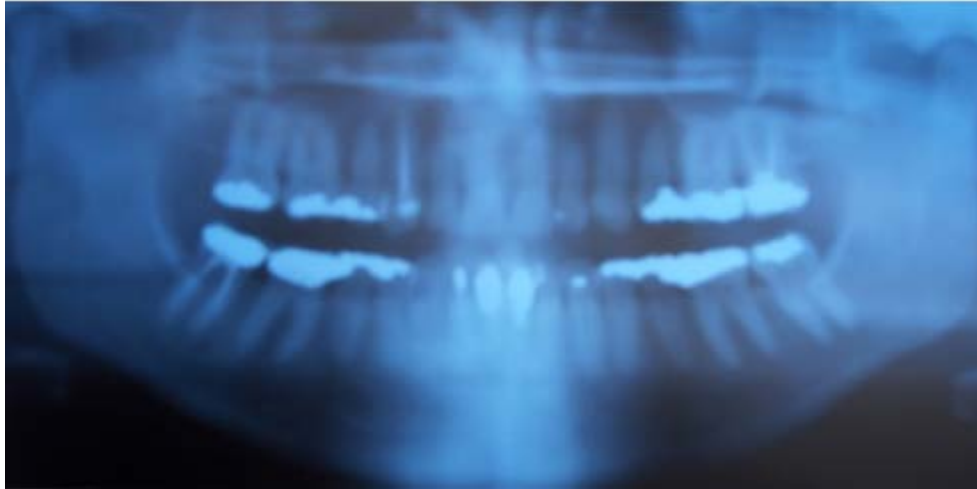
To understand why this is the correct answer, it's important to know about different types of dental x-rays and what they show. A "full mouth" x-ray, often referred to as a panoramic or panorex x-ray, captures the entire mouth in a single image, including all the teeth of the upper and lower jaw. This type of x-ray is particularly useful for getting a comprehensive view of the oral cavity and is commonly used to plan treatments that involve multiple teeth, like implants.

In contrast, a "bitewing" x-ray focuses on the crowns of the upper and lower teeth and is typically used to detect cavities between teeth where the crowns meet. Since the question specifically mentions that the x-ray shows implants rather than cavities and includes both the upper and lower teeth, the bitewing option can be ruled out.

The remaining answers are variations of the full mouth x-ray description. However, the answer that specifically and accurately describes the x-ray as showing teeth implants in the bottom jaw while being a full mouth x-ray is the most precise and correct choice. This eliminates any similar options that do not mention the implants or incorrectly describe another focus, such as caries (tooth decay), which is not indicated in the description provided.

Question: 2

Of the following, which does this dental x-ray show?



- A. Root canals.
- B. Periodontal disease.
- C. Dentures.
- D. Braces.

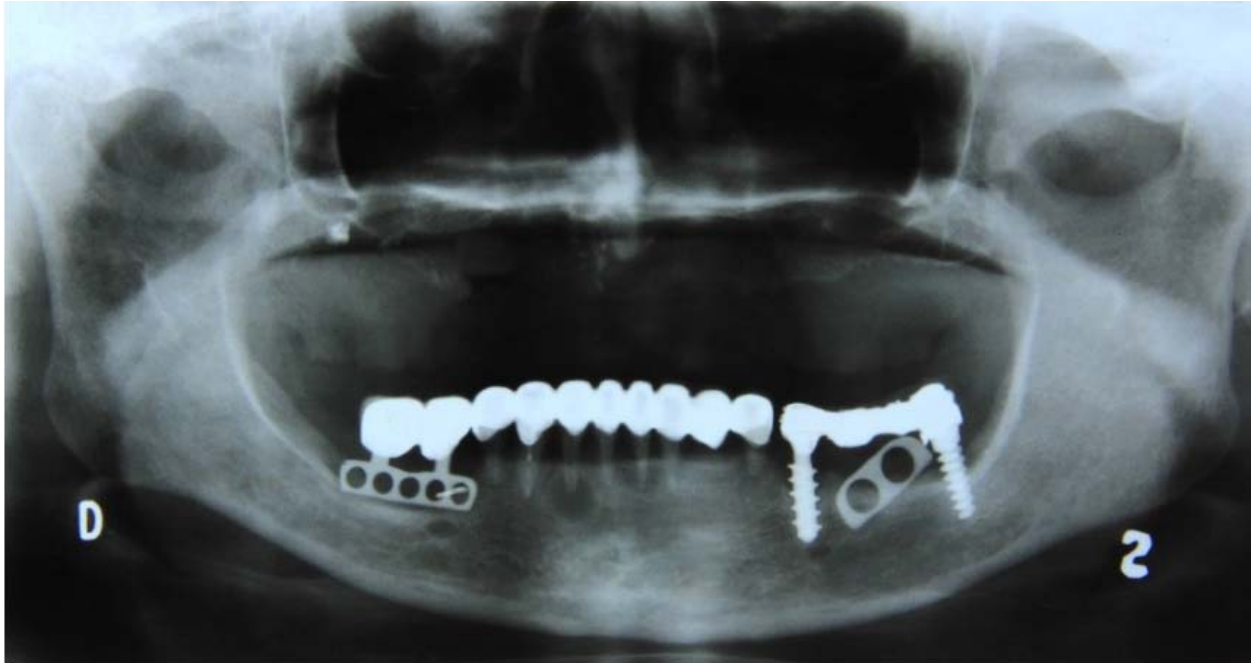Answer: A

Explanation:

The dental x-ray image is a full mouth panoramic view. It shows the teeth of a patient with root canals and several fillings.

Question: 3

This radiograph is of:



- A. Dentures.
- B. Braces.
- C. A retainer.
- D. All natural teeth.

Answer: A

Explanation:

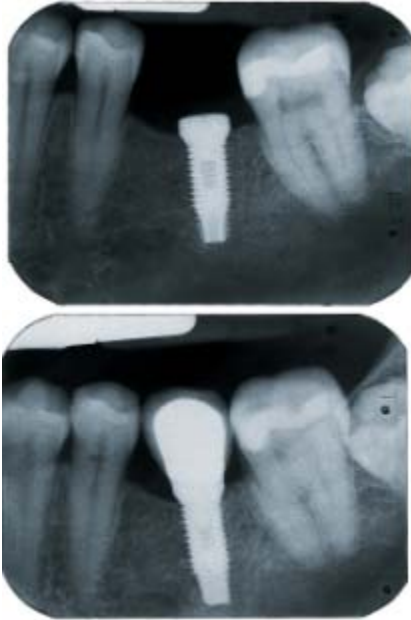The correct answer to this question is "Dentures." This is based on the visual evidence presented in the radiograph which shows the mandible along with what appear to be dentures. Dentures are prosthetic devices constructed to replace missing teeth, and they are supported by surrounding soft and hard tissues in the oral cavity. They can be either partial, replacing a few missing teeth, or complete, replacing all the teeth on either the maxillary or mandibular arch.

The option "Dentures" is repeated in the question as the answer for each incorrect option presented, such as braces, a retainer, or all natural teeth. Each of these options describes a different dental or orthodontic solution. Braces are used to correct the alignment of teeth and bite issues, not to replace missing teeth. A retainer is typically used after the removal of braces to keep teeth in their new position, again not serving the same purpose as dentures. Finally, "All natural teeth" implies an absence of any prosthetic or orthodontic appliances, which contradicts the presence of dentures indicated in the radiograph.

Therefore, given the radiographic evidence and the nature of the devices described, the only correct answer among the provided options is "Dentures." This is because the radiograph clearly shows the presence of prosthetic devices designed to replace missing teeth, which aligns with the definition and purpose of dentures.

Question: 4

What does this x-ray show?



- A. Gingivitis.
- B. TMJ.
- C. Osseo-implant.
- D. Tooth sensitivity.

Answer: C

Explanation:

In the context of interpreting an x-ray image in a dental setting, the correct identification of what the image shows is crucial for accurate diagnosis and treatment planning. In this case, the correct answer to the question "What does this x-ray show?" is "Osseo-implant."

An osseo-implant, more commonly known as a dental implant, is a prosthetic device used to replace missing teeth. Unlike dentures or bridges, dental implants are anchored directly into the jawbone, providing a stable and permanent solution for tooth loss. The term "osseo" refers to bone, indicating that the implant integrates with the bone tissue—a process known as osseointegration.

Dental implants are typically made of titanium, a material known for its strength and biocompatibility, meaning it is not rejected by the body. The implant serves as an artificial root, onto which a crown (a replacement tooth) can be mounted. Over time, the jawbone grows around the implant, securing it in place and allowing it to function similarly to a natural tooth root.

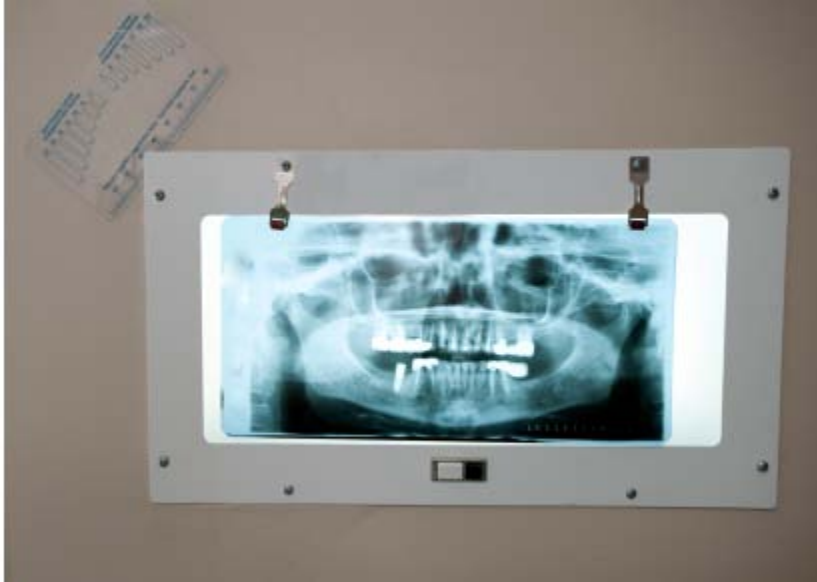The x-ray in question likely shows the dental implant embedded in the jawbone. On an x-ray, the implant appears as a distinct, typically screw-like structure within the bone. It is differentiated from natural teeth and other dental work by its unique shape and the shadows it casts on the x-ray due to the material's density.

Identifying an osseo-implant in an x-ray is important for several reasons. It helps in assessing the positioning and integration of the implant, planning further restorative procedures, and monitoring the overall health of the surrounding bone and tissues. Incorrect identification could lead to inappropriate treatment, which can compromise the health of the implant and the patient's oral health overall.

Therefore, recognizing an osseointegrated implant on an x-ray is a fundamental skill for dental professionals involved in implantology and restorative dental treatments.

Question: 5

According to the patient's x-ray, what is true?



- A. Patient has one extra tooth.
- B. Patient has two extra teeth.
- C. Patient has three extra teeth.
- D. Patient is missing teeth.

Answer: D

Explanation:

The question revolves around interpreting a dental x-ray to determine the condition of the patient's teeth. The correct answer, as provided, is that the patient is missing teeth.

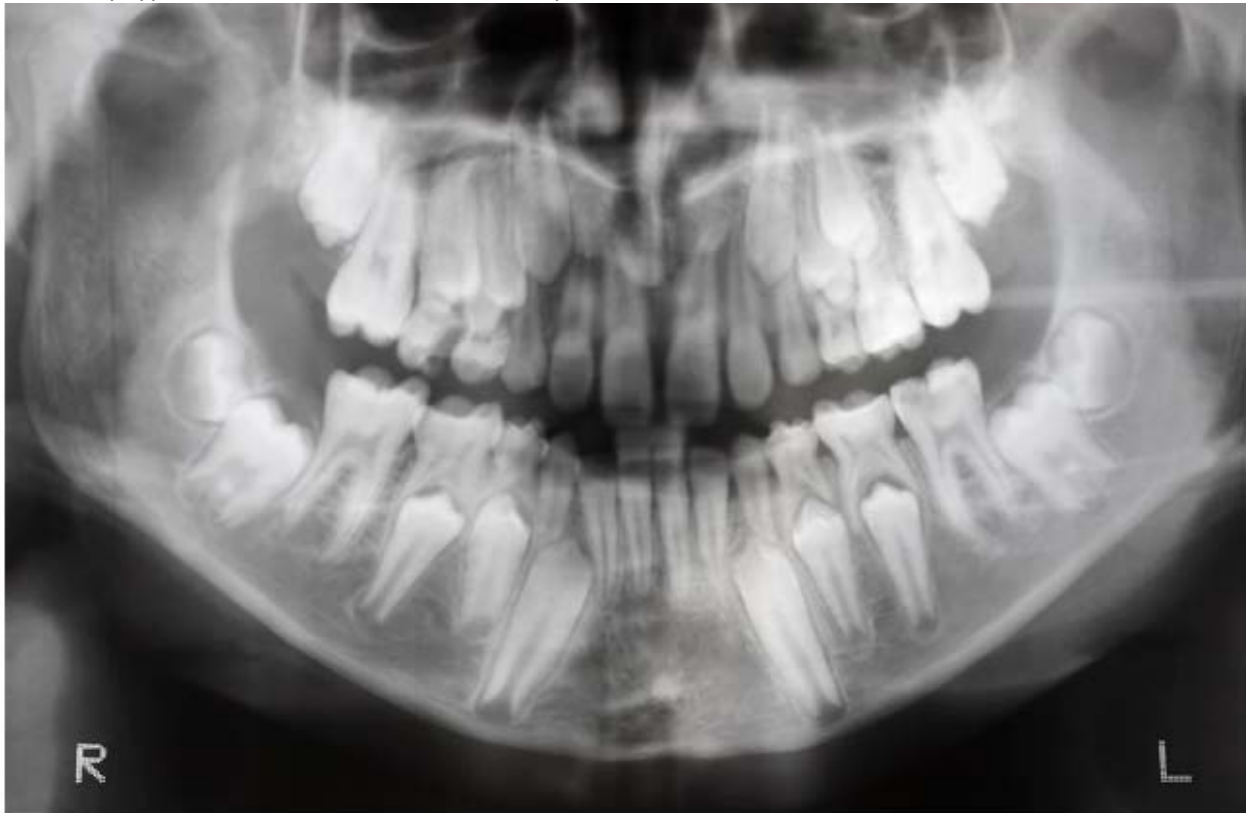In the context of the x-ray, even though multiple dental procedures and conditions are evident, the focus is on identifying whether there are missing teeth. Missing teeth in a dental x-ray are typically evident due to the absence of teeth in locations where normally teeth should be present. This can appear as clear gaps or spaces between the remaining teeth, or as areas where prosthetic devices such as bridges or implants are used to replace the original teeth.

The description of the x-ray confirms that the patient has had extensive dental work, including the installation of crowns, bridges, dental implants, veneers, and root canals. Each of these treatments serves different purposes: - **Crowns** are used to cover or "cap" a damaged tooth, enhancing its appearance and strength. - **Bridges** are used to fill the gap created by one or more missing teeth, anchoring onto adjacent teeth or dental implants. - **Dental implants** serve as replacements for the roots of missing teeth and are typically fitted with a crown or a bridge. - **Veneers** are thin covers placed over the front part of the teeth to improve aesthetics. - **Root canals** are procedures to treat infected or decayed teeth, preserving the tooth's shell while removing its infected core.

Given that the x-ray indicates the use of bridges and dental implants, it is clear that there are missing teeth. Bridges and implants are direct indicators of tooth loss as they are commonly employed to replace or support the structure and functionality of missing teeth. Hence, regardless of the presence of additional dental work, the direct observation relevant to the question is the confirmation of missing teeth, which aligns with the correct answer provided.

Question: 6

How many types of teeth are visible in this x-ray?



- A. Four.
- B. Three.
- C. One.
- D. Two.

Answer: D

Explanation:

This x-ray shows two types of teeth: the primary and permanent teeth are visible.

In dental terminology, "primary" teeth refer to what are commonly known as baby teeth or milk teeth. These are the first set of teeth that develop in young children. Primary teeth are typically lighter in color and smaller in size compared to their successors. They begin to appear when a baby is about six months old and are important for a child's early dental development, aiding in speech, chewing, and holding space for future permanent teeth.

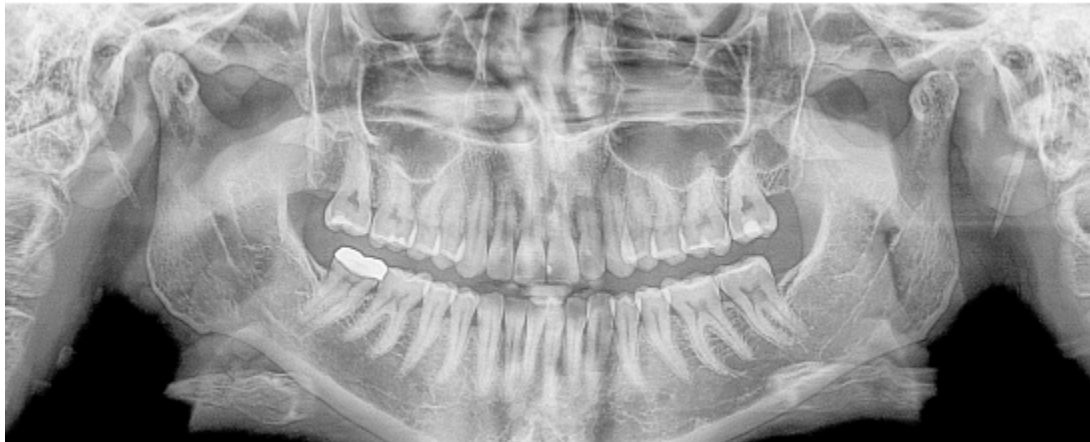Permanent teeth, also known as secondary or adult teeth, replace the primary teeth. These teeth start to develop around the age of six, and the transition can last into early adulthood. Permanent teeth are generally larger, stronger, and darker in shade compared to primary teeth. They are meant to last a lifetime and include varieties such as incisors, canines, premolars, and molars.

The x-ray in question likely shows both primary teeth that are still present in the mouth and permanent teeth that have either fully formed in place of primary teeth or are emerging. This dual presence is typical in pediatric patients who are in the transitional phase of losing their primary teeth and gaining their full set of permanent teeth, commonly known as the mixed dentition phase.

Understanding these types through an x-ray is crucial for dental professionals to evaluate dental health, alignment, and development, ensuring proper intervention if necessary. In conclusion, this x-ray exemplifies a typical scenario in pediatric dentistry where both primary and permanent teeth are visible, confirming the presence of two different types of teeth.

Question: 7

How many crowns does the patient have?



- A. 4
- B. 1
- C. 3
- D. 2

Answer: B

Explanation:

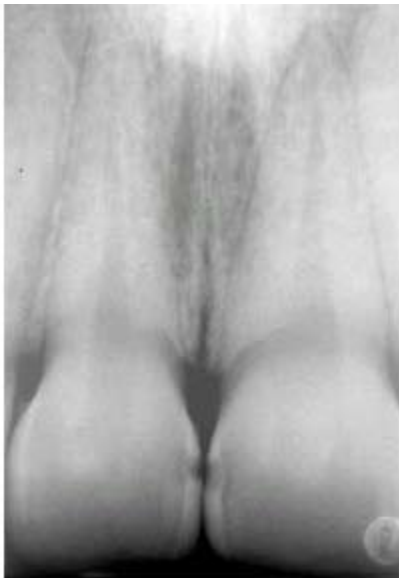To answer the question regarding the number of crowns the patient has, it is essential to refer to the panoramic x-ray provided. A panoramic x-ray is a type of full-mouth X-ray that captures the entire dental arch of a patient in a single image. It is commonly used to provide a comprehensive view of the teeth, jawbones, and surrounding structures, which helps in diagnosing dental conditions and planning treatments.

In this specific case, the x-ray reveals that the patient has one crown. Dental crowns are cap-like structures placed over a tooth, primarily used to restore its shape, size, strength, or to improve its appearance when a tooth is damaged or decayed. Crowns can be made from various materials such as porcelain, ceramic, metal, or resin.

Besides the crown, the x-ray also shows several cavities. Cavities, or dental caries, are decayed areas of teeth that develop into tiny openings or holes. They are caused by a combination of factors, including bacteria in the mouth, frequent snacking, sipping sugary drinks, and not cleaning teeth well. The presence of one crown and several cavities indicates specific dental health issues and treatment history. The crown suggests a previous significant tooth repair, while the cavities point to areas where oral hygiene may need improvement or where further dental treatments might be necessary to prevent further decay and maintain oral health. From this information, the correct answer to the question, as shown in the x-ray, is that the patient has one crown. This answer is deduced by clearly identifying the crown among other dental structures and issues such as cavities, as visible in the panoramic x-ray.

Question: 8

What is the location of the cavities in this patient's teeth.



- A. In the back molars.
- B. Between the front teeth.
- C. In all of the wisdom teeth.
- D. The patient has no cavities.

Answer: B

Explanation:

The question pertains to identifying the location of cavities in a patient's teeth based on an x-ray image provided. Cavities, also known as dental caries, are areas of decay caused by bacteria that demineralize and destroy the hard tissues of the teeth. These are common in areas where dental hygiene is compromised and can occur between teeth, on the biting surfaces, and around old fillings or damaged areas of teeth.

In the specific case discussed in the question, the correct answer is that the cavities are located between the front teeth. This region, often referred to as the interdental or interproximal space, is particularly susceptible to the development of cavities for several reasons. Firstly, it is a region that easily traps food

particles and is less efficiently cleaned by regular brushing, especially if not complemented by flossing. Secondly, these areas are less exposed to the natural self-cleaning actions of the tongue and saliva, making them more prone to plaque accumulation.

The x-ray image serves as a crucial diagnostic tool in confirming the presence of cavities. On dental x-rays, cavities typically appear as dark spots or shadows indicating areas where the tooth structure has been compromised. The radiographic evidence of cavities between the front teeth likely shows such darkened areas on the sides of these teeth where they touch each other. This is consistent with the description provided in the correct answer.

It's important to note that the other options provided in the question—cavities in the back molars, in all of the wisdom teeth, or the absence of any cavities—were incorrect based on the x-ray findings. Molars and wisdom teeth are common locations for cavities due to their complex surface anatomy that makes them harder to clean. However, in this specific patient's case, the x-ray did not show evidence of cavities in these areas.

Identifying the correct location of cavities helps in planning appropriate dental treatments, which may include fillings, crowns, or other restorative procedures to prevent further decay and restore the function and aesthetics of the teeth. Early detection and treatment are crucial in preventing more severe dental problems and maintaining overall dental health.

Question: 9

What line will help keep the patient's chin from tipping too far up or down?

- A. Alar-tragus line.
- B. Bite block.
- C. Edentulous guide.
- D. Endoray II film holder.

Answer: A

Explanation:

The correct line to help keep the patient's chin from tipping too far up or down during dental imaging is the *Alar-tragus line*.

The Alar-tragus line, often used in panoramic radiography, plays a crucial role in ensuring the patient's head is positioned accurately. This imaginary line runs from the *alar* (outer part of the nostril) to the *tragus* (the small cartilaginous bump in front of the ear canal). Proper alignment along this line is essential for capturing a clear and distortion-free panoramic image.

When positioning a patient for a panoramic X-ray, the technician adjusts the patient's head so that the Alar-tragus line is parallel to the floor. This alignment helps to prevent the chin from tipping too far upward or downward. If the chin is tilted too high, it can lead to a foreshortening of the jaw in the image, making the lower structures appear smaller than they are. Conversely, if the chin is tilted too low, it can cause elongation, making the lower jaw structures appear unnaturally stretched.

In most panoramic X-ray machines, there are visual aids or markers to help the operator in aligning the Alar-tragus line correctly. Ensuring this line is properly aligned is fundamental in achieving a diagnostic-quality image, which is crucial for accurate assessment and treatment planning in dentistry.

Therefore, the Alar-tragus line is not just a guideline but a critical component in dental imaging that aids in the correct positioning of the patient, thus ensuring that the resulting images are as informative and useful as possible.

Question: 10

What will help a patient with a severe gag reflex?

- A. Distract the patient.
- B. Start with the largest film size.
- C. Use a bite rod.
- D. Use a round film holder.

Answer: A

Explanation:

When a patient has a severe gag reflex, managing this reflex effectively is crucial for the successful completion of dental procedures. A gag reflex is a natural defense mechanism that helps prevent choking or swallowing foreign objects. However, it can pose challenges during dental treatments, especially those that involve placing objects like X-ray films or dental instruments in the mouth.

One effective strategy to help a patient with a severe gag reflex is to distract the patient. Distraction techniques can redirect the patient's attention away from the procedure and reduce the likelihood of triggering the gag reflex. Various methods can be employed for distraction: - Engaging the patient in conversation on unrelated and pleasant topics. - Allowing the patient to listen to music through headphones. - Encouraging the patient to focus on breathing exercises or visualization techniques.

In addition to distraction, there are practical approaches in handling dental tools and materials that can help minimize gag reflex activation: - **Starting with smaller film sizes:** For dental X-rays, it's beneficial to begin with smaller film sizes if the patient experiences a strong gag reflex. This minimizes the amount of foreign material in the mouth and allows the patient to gradually adapt to the sensation. - **Progressing to larger film sizes gradually:** After the patient becomes comfortable with smaller films, gradually introduce larger sizes. This step-wise approach can help desensitize the gag reflex over time.

Other tools and techniques that might be considered include: - **Using a bite rod:** This can help stabilize the film and reduce the need for the patient to adjust their mouth too frequently, which might trigger gagging. - **Employing a round film holder:** This type of holder might fit more comfortably in the mouth, reducing discomfort and potential gag reflex activation.

Overall, managing a patient with a severe gag reflex requires a thoughtful approach, combining psychological techniques such as distraction with practical adjustments to the dental tools and procedures. By doing so, dental care professionals can ensure a more comfortable and successful treatment experience for their patients.

For More Information – **Visit link below:**

<https://www.examkill.com/>

Sales: sales@examkill.com

Support: support@examkill.com

FEATURES:

- 100% Pass Guarantee
- 30 Days Money Back Guarantee
- 24/7 Live Chat Support (Technical & Sales)
- Instant download after purchase
- 50,000 +ve Reviews
- 100% Success Rate
- Discounts Available for Bulk Orders
- Updates are free for 90 days
- Verified answers by experts

